

# Prominent tooth in front

## Patient

- 20 year old female

## Diagnosis

- Dental crowding with blocked right canines both arches
- Class II dental occlusion
- Upright incisors
- Dental crowding

## Treatment

- Initial non-extraction alignment and re-evaluate for extractions
- Torque correction right canines
- Elastics for vertical and anterior-posterior correction

## Brackets

- Number repositioned 0

## Appointments

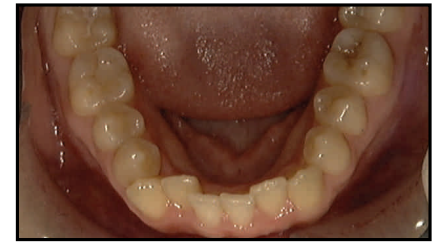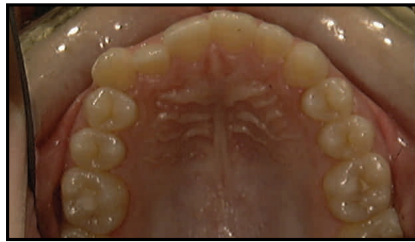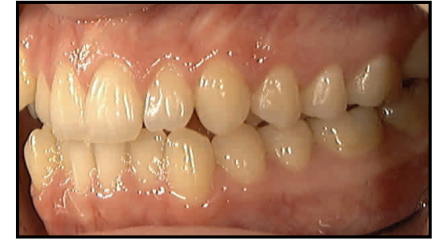
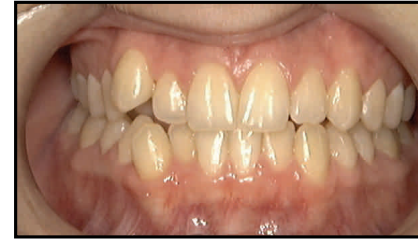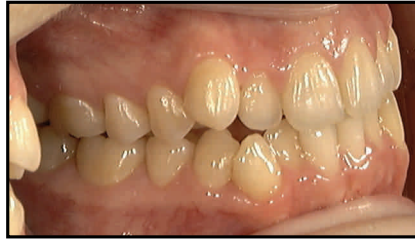- Total 8
- Detail wire bends 5

## Expected treatment time

- 18 months

## Actual treatment time

- 15 months

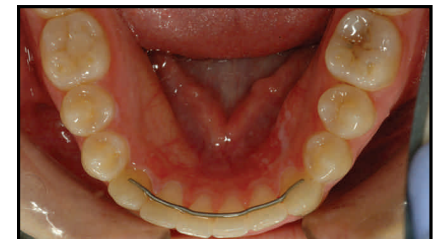
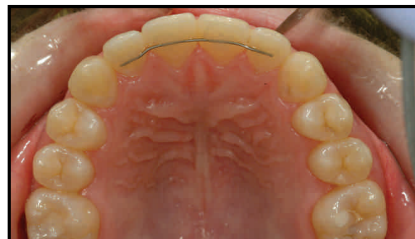
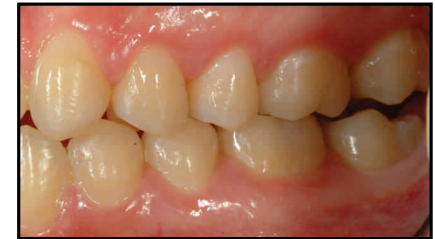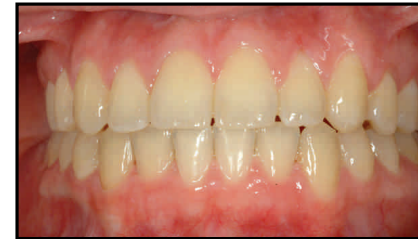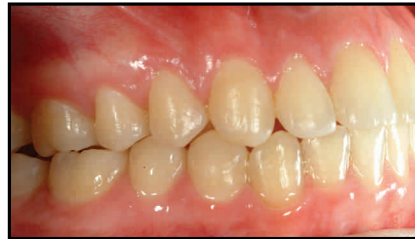Pre-treatment  
Images

OrthoCAD



IT'S ABOUT TIME



Post-treatment  
Images

Courtesy of Michael Mayhew, DDS, MS