

Orthodontic evaluation

Patient

- 13 year old male

Diagnosis

- Convex profile, mandibular deficient in length
- Class II skeletal
- Mandibular crowding
- Deep bite

Treatment

- Non-extraction alignment
- Level mandibular arch
- Intrude maxillary central incisors

Brackets

- Number repositioned 0

Appointments

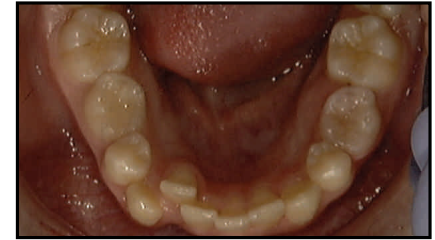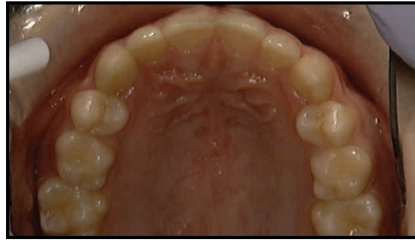
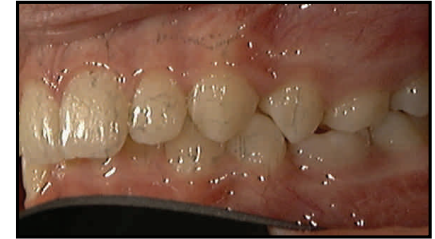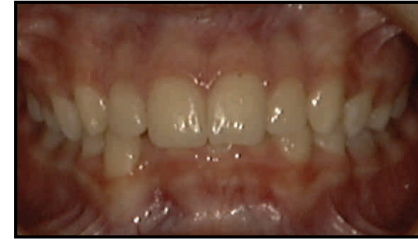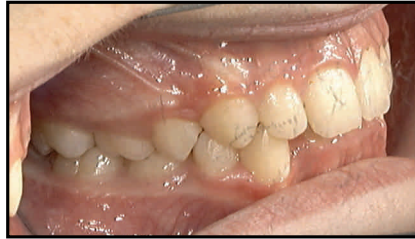- Total 9
- Detail wire bends 1

Expected treatment time

- 18 months

Actual treatment time

- 18 months

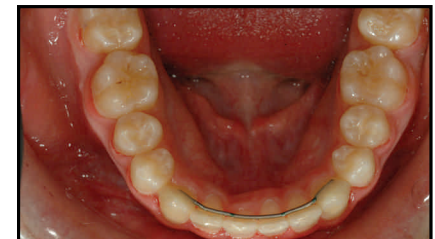
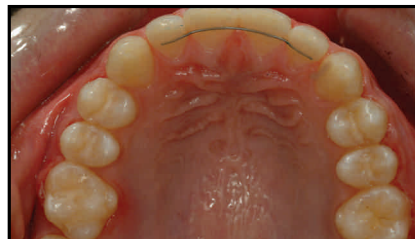
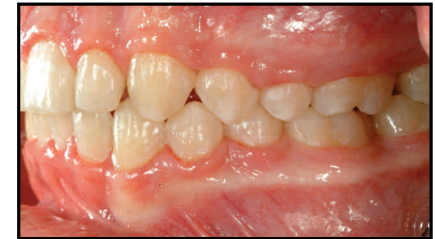
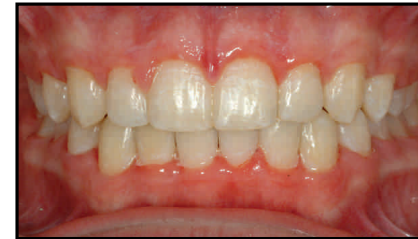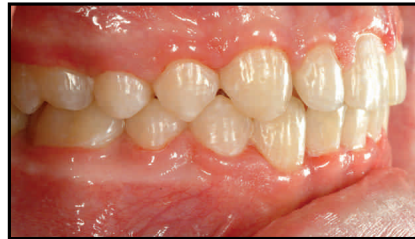Pre-treatment
Images

OrthoCAD



IT'S ABOUT TIME



Post-treatment
Images