

Better alignment

Patient

- 11 year old female

Diagnosis

- End to end dental relations
- Mild Class II skeletal
- Excess overbite and overjet
- Dental malalignment

Treatment

- Non-extraction alignment
- Mild arch development with wires
- Class II elastics for anterior-posterior change
- Level lower arch

Brackets

- Number repositioned 2

Appointments

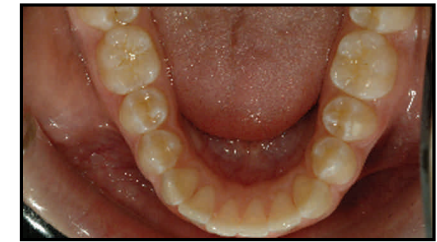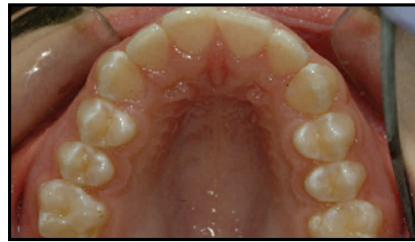
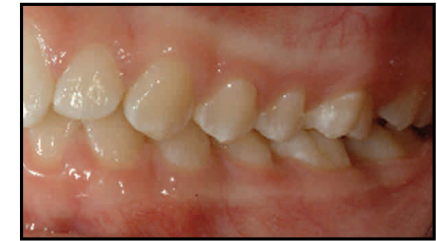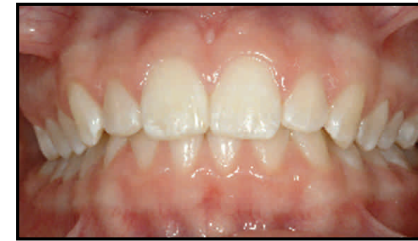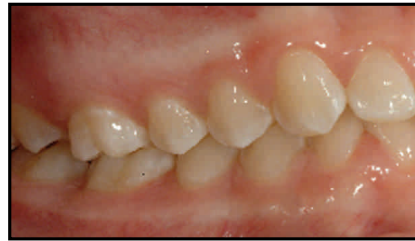- Total 7
- Detail wire bends 4

Expected treatment time

- 24 months

Actual treatment time

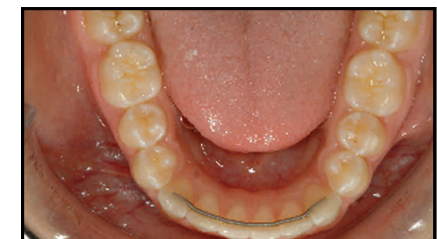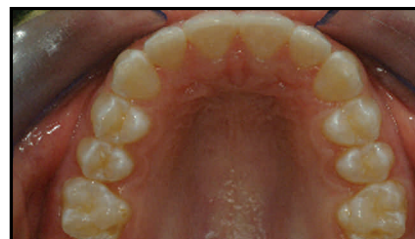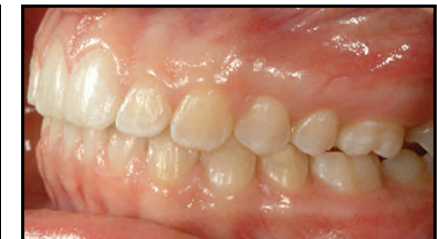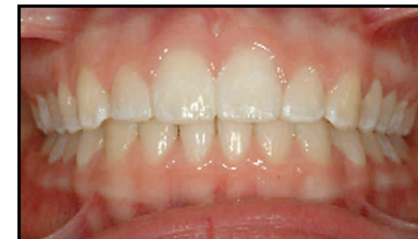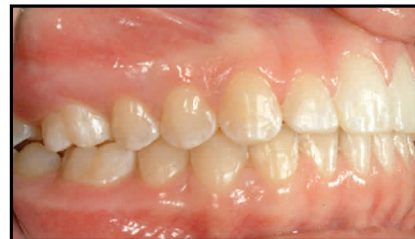- 16 months



OrthoCAD



IT'S ABOUT TIME



Courtesy of Michael Mayhew, DDS, MS