

Crowding

Patient

- 12 year old female

Diagnosis

- Class II skeletal, Class I molar relations
- Dental malalignment
- Facial blocked maxillary canines

Treatment

- Non-extraction alignment
- Night time wear of high pull headgear to control maxillary incisor position during initial alignment
- Elastics for vertical and anterior-posterior correction

Brackets

- Number repositioned 0

Appointments

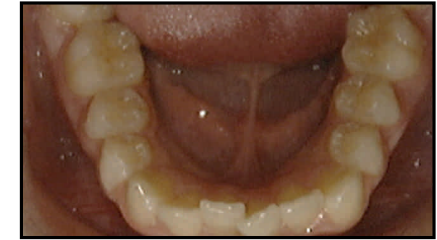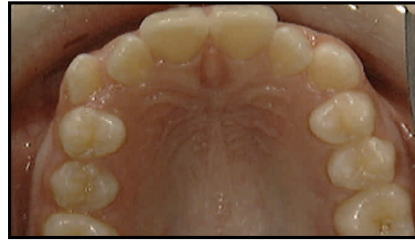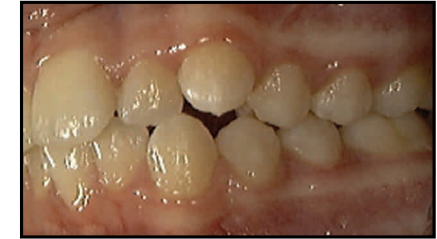
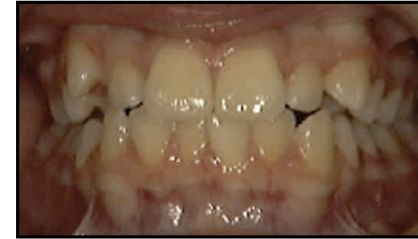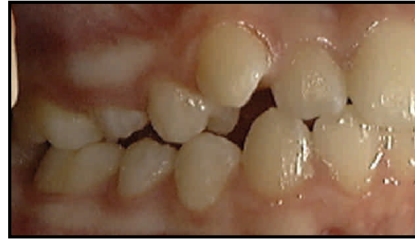- Total 8
- Detail wire bends 2

Expected treatment time

- 24 months

Actual treatment time

- 16 months

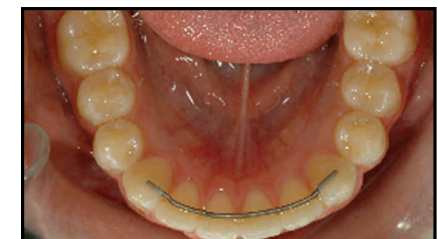
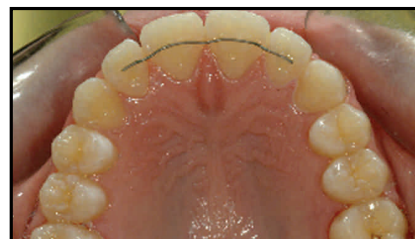
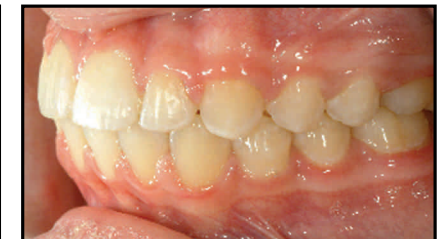
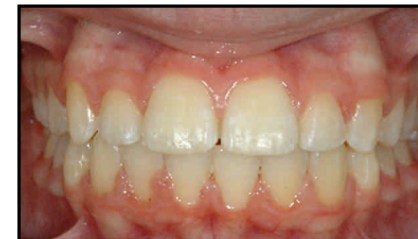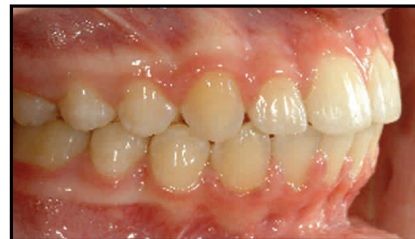Pre-treatment
Images

OrthoCAD



IT'S ABOUT TIME



Post-treatment
Images

Courtesy of Michael Mayhew, DDS, MS